



## Ultrasound accelerated thrombolysis for therapy of arterial and venous thrombosis – initial experience in the Military Medical Academy in Belgrade

Tromboliza ubrzana ultrazvukom u terapiji arterijske i venske tromboze – početno iskustvo u Vojnomedicinskoj akademiji u Beogradu

Jelena Kostić\*, Siniša Rusović†, Zoran Trifunović‡§, Miodrag Mihajlović†,  
Vlastimir Marinković†, Milan Šćepanović†, Milan Dobrić\*,  
Slobodan Obradović§||

University Clinical Center of Serbia, \*Clinic for Cardiology, Belgrade, Serbia; Military Medical Academy, †Institute of Radiology, ‡Clinic for Cardiac Surgery, §Clinic for Emergency and Internal Medicine, Belgrade, Serbia; University of Defence, ||Faculty of Medicine of the Military Medical Academy, Belgrade, Serbia

### Key words:

venous thrombosis; ultrasonic therapy; thrombolytic therapy; treatment outcome.

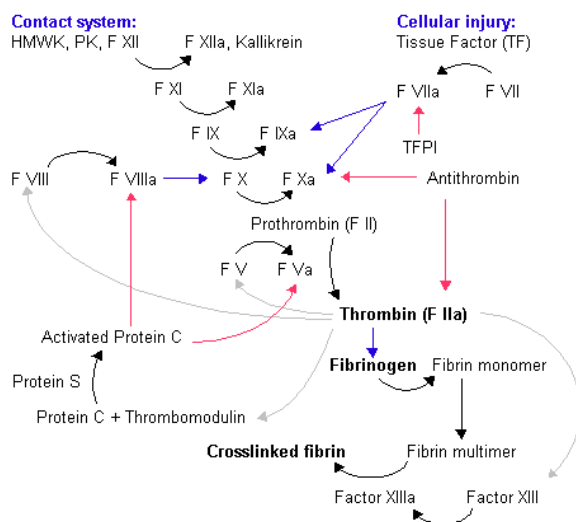
### Ključne reči:

tromboza, venska; lečenje ultrazvukom; fibrinolitici; lečenje, ishod.

### Introduction

Hemostatic system has been developed to preserve the integrity of circulation. Main components of hemostasis are: blood vessel wall, plasma proteins (coagulation and fibrinolytic factors), platelets and other blood elements such as monocytes, red blood cells, etc.<sup>1</sup>. All system components function interconnected. Coagulation plasma proteins normally circulate in its biologically inactive forms as proenzymes. Coagulation is the process which leads to formation of blood clots and turning from liquid to solid. It is very important, since if it does not work, it may cause bleeding disorders and if it works in excess it can lead to thrombosis. The whole process of clotting is based on many parts, each component performing a small but vital role. The clotting cascade details this (Figure 1), but in essence, damaged vessel walls cause platelets to get joined together by fibrin, forming a tight clot. Thus, the three main components of the coagulation process are: platelets, fibrin, and the damaged endothelium. Whilst platelets are naturally present in blood, fibrin is formed through the clotting cascade. There are two pathways: the contact activation pathway (also known as the intrinsic pathway) and the tissue factor pathway (known as the extrinsic pathway). The process of activation of platelets and fibrinogen in inappropriate blood vessel can end in thrombus formation, so that thrombosis may be considered excessive hemostasis in the wrong place<sup>2-4</sup>. Thrombi can occur in any part of the vascular system as a result

of imbalance between the hemostatic system. The sequence of events in thrombus formation depends on the velocity of circulation: arterial (fast) and venous (slow).



**Fig. 1 – Coagulation cascade.**  
HMWK – high molecular weight kininogen; PK – prekallikrein; F – factor; TFPI – tissue factor pathway inhibitor ([https://sh.wikipedia.org/wiki/Zgru%C5%A1avanje\\_krvi](https://sh.wikipedia.org/wiki/Zgru%C5%A1avanje_krvi))

The causes of arterial thrombosis can be atherosclerosis, coagulation disorders such as antiphospholipid antibodies syndrome, protein C resistance (factor V Leiden), the lack of protein C or S, heparin induced thrombocytopenia, essential thrombocytopenia and hyperhomocysteinemia<sup>5-7</sup>.

Pulmonary thromboembolism (PTE) and deep vein thrombosis (DVT) is almost impossible considered separately, and is often together referred as venous thromboembolism (VTE). One or more factors of Virchow's triad (hemodynamic changes, endothelial injury/dysfunction and hypercoagulability of blood) are almost always the cause of VTE. Thrombotic process begins in the venous valve cusps, spreads and can lead to complete occlusion of the lumen and venous tributaries and embolization<sup>8,9</sup>. The incidence of DVT is common in surgical and other disease in which there is inactivation of the muscle venous pump. Other causes may include: external obstruction, strictures, scars, pressures from surrounding structures, often tumor mass. PTE is a common, serious and potentially fatal complication that occurs when a clot from the deep vein, usually the lower limb or pelvic, cause embolisation of pulmonary arterial circulation. Rarely the source of emboli can be of the vena cava thrombus, deep veins of the upper extremities and the right heart.

### New thrombolytic technique

EkoSonic™ Mach4 (EKOS® Corporation, Bothell, WA) endovascular system with rapid pulse modulation (RPM) is designed for the dissolution of vascular blood clots. EkoSonic™ is the only endovascular system that can deliver microsonic energy and thrombolytic drug simultaneously, providing safer, faster and more complete thrombus removal by accelerating dissolution. It is intended for controlled and selective infusion of thrombolytic drugs into the peripheral vasculature and pulmonary arteries. EkoSonic™ device obtain access for standard percutaneous endovascular procedures, 6F sheath is preferred. The system consists of a reusable and single use parts. The reusable parts are the control unit which provides ultrasound energy and the user interface, with his own connector interface cable (CIC). Single use parts of this device are: intelligent drug delivery catheter (IDDC) and microsonic device (MSD) (Figure 2).

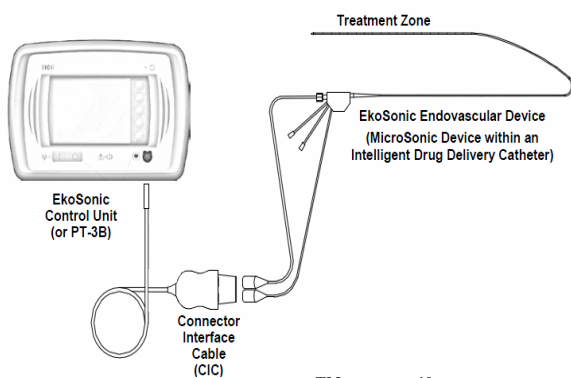


Fig. 2 – EkoSonic™ device<sup>10</sup>.

EkoSonic control system generates ultrasonic energy waves at the treatment zone through piezoelectric transduction of radiofrequency (RF) energy generated by the control unit. The device frequency ranges from 2.05 to 2.35 MHz pulse modulated. The maximum output power is 50 W (30 W average), maximum temperature is 43°C. The control unit monitors output power and temperature of the endovascular unit. It has the safeguard circuits to prevent deviation of these parameters from preset range. If there is a disorder, the system automatically turns off.

Infusion catheter (IDDC) has a unique design (Figure 3) with two separate lumens, one for the drug delivery through the side holes, and the central lumen for the exchange of the guide wire and MSD, as well the delivery of saline for cooling the ultrasound probes. The IDDC catheter has two markers on the distal end between which are located side holes – treatment zone of the catheter. Infusion of the drug and saline are administered *via* a standard infusion clinical pump. The MSD device has 30 fully isolated, radiopaque marked probes in its distal part. Both catheters exist in different length for different vessel localization and thrombus length. The available lengths are: 106 cm working length with the treatment zone 6, 12, 18, 24, 30, 40, 50 cm and 135 cm working length with the treatment zone 12, 30, 40, 50 cm.

### How it works?

When it comes to the formation of thrombus in peripheral blood vessels that obstruct the lumen and prevent normal blood flow or in PTE as the clot forms, plasminogen is incorporated into the fibrin<sup>11</sup>. In order to resolve the clot thrombolytic agent must reach the receptor sites on the plasminogen. The EkoSonic™ endovascular system facilitates this process. It simultaneously releases thrombolytics and ultrasound energy within the thrombus<sup>12,13</sup>. Delivering drug without ultrasound may limit its dispersion, as the drug will follow the path of least resistance along the side holes of non ultrasound catheter. By contrast activating the EkoSonic™ endovascular system it generates a radial pressure within the treatment zone around the catheter<sup>14</sup>. The pressure effectively drives the drug into the thrombus and

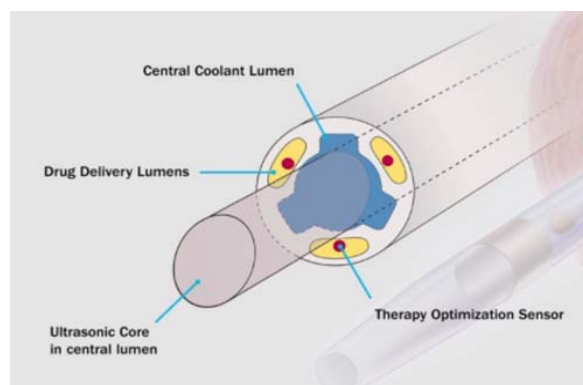


Fig. 3 – Cross section of the intelligent drug delivery catheter<sup>10</sup>.

immediately accelerates the dispersion of the drug. At the same time acoustic energy conditions the clot by thinning fibrin into individual strands. This increases the pore size and allows more effectively delivery of the drug deep inside the thrombus. As the drug moves further in the fibrin mesh, it surrounds each fibrin strand and binds with newly exposed plasminogen activator receptor sites. The fibrin strands begin to dissolve releasing red blood cells and other blood components trapped into the fibrin matrix.

### **Our initial experiences**

Using this method patients have been treated in Radiology Institute in Military Medical Academy in Belgrade since 2013 until February 2017, co working with clinicians from Cardiac Surgery Clinic, Vascular Surgical Clinic and Clinic for Emergency and Internal Medicine. Purpose of the report is to show efficiency of method for dissolving thrombus in targeted blood vessel. All patients had signs of arterial or venous system thrombosis. The diagnosis of thrombosis of the vessel was established on the basis of clinical examination, laboratory findings, echocardiography, multidetector computed tomography (MDCT) angiography or conventional angiography. Following the established diagnosis all the patients were subjected to treatment with ultrasound accelerated thrombolysis by the assigned protocol.

Four patients had thrombosis of femoropopliteal bypass graft, one had thrombosis of the superior mesenteric artery, one with thrombosis of vena cava and twenty patients with PTE. Depending on the location of thrombosis and its duration clinical symptoms were different. The duration of symptoms in patients varied from rapid onset up to six months. There had been treated acute (< 14 days), subacute (15–28 days) and chronic (> 28 days) old thrombosis. After abovementioned examination all the patients were presented to the Catheterization Laboratory.

### **Device and procedure description**

Percutaneous transfemoral or transjugular approach was used. After the angiography of the occluded vessel, through the 6F sheath guide wire was introduced into the blood vessel that was necessary to treat passing through the entire length of the clot under the control of fluoroscopy. Hydrophilic guide wire of 0.035 inch was used. Then the IDDC catheter was inserted over the guide wire until the tip of the catheter passes entirely through the clot with the tip in healthy part of the vessel. The guide wire was then pulled out and replaced by the MSD with positioning of the radiopaque probes within the proximal and distal marker on the IDDC. After connecting drug solution and saline with the adequate ports and attaching the CIC with IDDC and MSD, treatment procedure was started. The duration of the therapeutic procedure depended on thrombus maturity and its size. The time ranged from 6 to 24 hours. Thrombolytic therapy [recombinant tissue plasminogen activator-tPa (rtPA) – alteplase] was given at the dose of 1–3 mg per hour. The solution was made as follows: 50 mg alteplase inserted into 500 mL of saline.

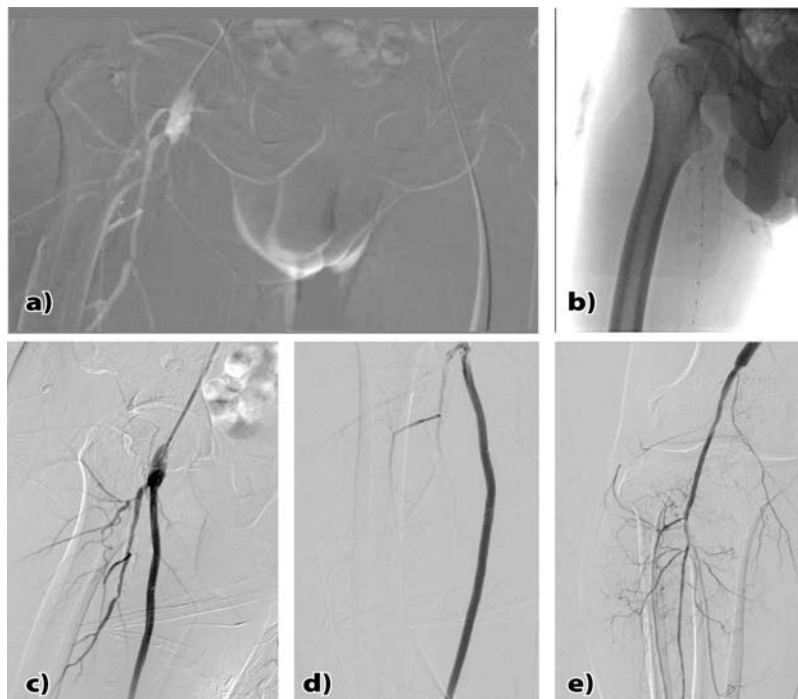
The drug was running through the standard infusion pump 5–15 mL per hour (depending on the required dose), saline solution for cooling the probe went 35 mL per hour. Upon completion of the therapy procedure the device was pulled out. Final angiography was made and MDCT angiography was made next day. Further monitoring of the patient's was clinical.

### **Views of individual patients performed**

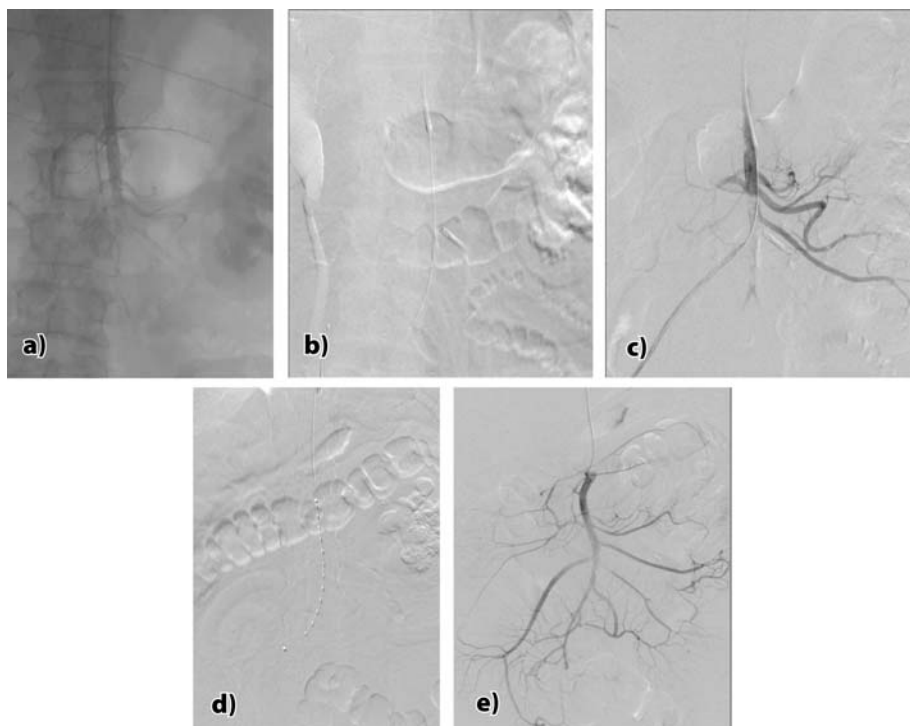
There were 4 patients 1–2 years after surgical revascularization of the lower limbs, femoropopliteal bypass grafts (due to occlusion of superficial femoral artery), with the presentation of symptoms that indicated graft occlusion. In 3 patients according to the medical history graft occlusion was subacute (up to one month), while one was chronic (up to 6 months). They all had clinical symptoms of chronic lower limb ischemia as they already had ischemic arterial disease, but they all complained on intermittent claudications, distance shortening. Claudication is defined as fatigue, discomfort or pain that occurs during exercise in a particular group of legs muscles. People with claudication have enough blood supply so in rest symptoms disappear<sup>15, 16</sup>. Patients with typical claudication described: pain, itching, pressure, cramping or fatigue in one or more muscle groups of the lower extremities. The symptoms are usually caused by exertion and subside during resting. Localization of claudications occurrence was distal to the diseased segment of the artery. Anatomic site of the lesion is usually associated with pain in the leg at a certain point. Patients complained of pain in the region below the knee, which is typical for the femoropopliteal or tibial artery disease. After confirmed diagnosis of thrombosis of femoropopliteal graft they received the therapy (ultrasound accelerated thrombolysis) which lasted for 6 hours at a dose of 1 mg per hour. After reestablishing perfusion in all four patients were detected stenosis at proximal or distal anastomosis which was solved by stent implantation (Figure 4). All given results refer to immediate founding after the intervention. The prognostic outcome of patients limb salvage in spite of complete resolution of thrombus depends on the condition of distal microvascular circulation.

Acute occlusion of the superior mesenteric artery appear in the patient on the third postoperative day after coronary artery bypass grafting (CABG) for myocardial revascularisation. The patient had strong, tearing pain in the abdomen, bowel peristaltic was not audible. After MDCT examination the occlusion of the superior mesenteric artery was found. First thrombus aspiration was done, by using the right coronary guiding catheter 7F (due to the larger lumen width) with no results. Then the ultrasound accelerated thrombolysis was applied for 6 hours at the dose rtPA 1 mg/hour. Near complete dissolution of the thrombus was achieved, soon after peristalsis was restored and the patient fully recovered (Figure 5).

Acute vena cava inferior thrombosis appeared after resection of the right liver lobe due to hepatocellular carcinoma. During the surgery, there was an iatrogenic lesion of the



**Fig. 4 – a) Occlusion of the right femoropopliteal graft; b) EkoSonic™ device into the graft; c) and d) Control angiograph by findings; e) Stent placement at the site of distal anastomosis.**



**Fig. 5 – a) Occlusion of *arteria mesenterica superior*; b) and c) Attempt of aspiration; d) EkoSonic™ device; e) Final angiogram.**

inferior vena cava that was resolved surgically. On the third postoperative day the patient developed symptoms of acute renal failure. MDCT examination showed thrombosis of the inferior vena cava, which starts from the hepatic vein stretching down and capturing the renal veins. Ultrasound accelerated thrombolytic therapy was applied for 24 hours with the dose of thrombolytic 1 mg/hour. Control angiography re-

led reestablished venous drainage. The patient recovered uneventfully with no further renal insufficiency.

There were twenty patients with PTE, treated with this method. Most of them had high risk for bleeding or were resistant to conventional therapy. In all patients were registered significant improvement of symptoms, decrease of systolic right ventricular pressure and decrease of thrombus burden on

control MDCT pulmoangiography. There were no intrahospital deaths in PTE patients treated with EKOS (Figure 6).

### Comparison to other techniques

EkoSonic™ Mach4 (EKOS® Corporation, Bothell, WA) infusion system with an ultrasound probe was designed in 1996. The Food and Drugs Administration (FDA) and European Community mark (CE mark) for therapeutic use in peripheral blood vessels was received in 2004.

For systemic administration of rtPA doses are 0.6–0.9 mg/kg for 2 hours in infusion, with a starting bolus of 10 mg previously, but not exceeding 100 mg in total. This way of giving carries a high risk of bleeding and contraindications for administration are hemorrhagic stroke or stroke of unknown etiology anytime, ischemic stroke in the previous 6 months, central nervous system damage or neoplasm, recent trauma and/or surgical intervention, gastrointestinal bleeding in preceding month and positive hemorrhagic diathesis. Relative contraindications are: transitory ischemic attack in the preceding 6 months, oral anticoagulant therapy, pregnancy or the first week postpartum, advanced liver disease, infective endocarditis, active peptic ulcer, refractory hypertension (systolic pressure greater than 180 mmHg).

The total dose of the given thrombolytic therapy using the ultrasound accelerated thrombolytic device is 50–70% smaller comparing to the systemically given.

Classic transcatheter delivering of the drug entails the necessary long time, leaving intraluminal catheter 48 hours or more, which carries more than 10% higher risk of bleeding<sup>17</sup>. This method increases the length of time of therapy, which brings along delivering greater total dose and thus a higher risk of bleeding. According to the recommendations of the American College of Chest Physicians (ACCP) from 2008, in order to reduce the period of drug administration through a catheter, proposed was combining with mechanical method for faster removal of thrombus and thereby shortening the duration of the procedure and the total given dose<sup>18</sup>. Pharmacomechanical thrombolysis involves a longer time of exposal to radiation to patients and staff, the risk of residual thrombus. Those methods mechanically remove a clot only from the place where the aspiration is made or clot is removed in another manner, therapy is usually continued with thrombolytic. There is always hemolysis, high risk of distal remobilization<sup>19</sup> as well as mechanical injury of the vessel wall and vein valves<sup>20, 21</sup>. The difference in protocols and duration of procedures and last but not the least important is that the success rate of the three most common methods that are in use are very different. The protocol for the use of the EKOS® system is as follows: image occlusion, passing a guide wire through the thrombus, catheter insertion IDDC, replacement guide wire catheter MSD, release therapy (thrombolysis plus ultrasound) (Figure 7). The protocol for the use of the trellis system is quite complicated and time-

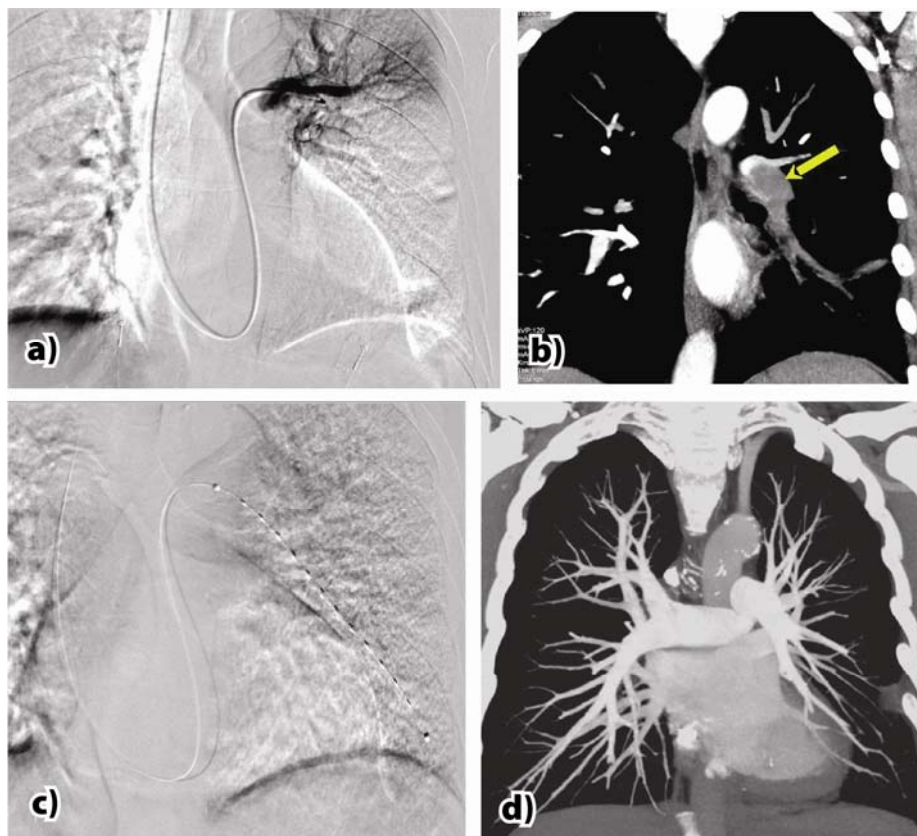



Fig. 6 – a) and b) Thrombus in the left pulmonary artery; c) EkoSonic™ device; d) Final multidetector computed tomography with pulmonary angiography.



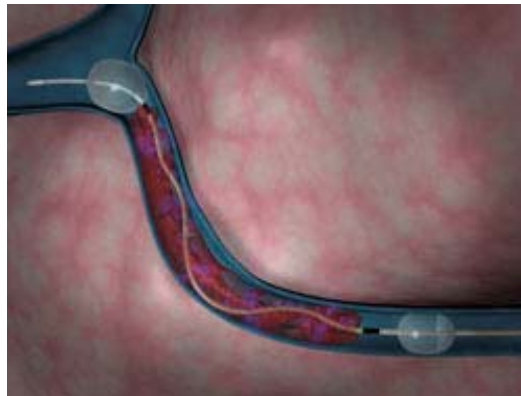
**Fig. 7 – Ultrasonic pressure waves encompass entire vessel.**

consuming and involves: image occlusion, passing a guide wire through the thrombus, place trellis device into clot, inflate the first balloon, infuse contrast to confirm flow is occluded, inflate second balloon, infuse treatment dose of thrombolytic, insert dispersion wire, attach trellis device unit and activate, manually control drive speed (maximum balloon inflation time: 15 minutes per position), deflate proximal balloon, advance introducer sheath to near distal balloon, aspirate residual thrombus, the distal balloon deflation, image vessel and assess progress. If there is a residual thrombus, the entire procedure is repeated (Figure 8). The entire procedure should not take longer than 60 minutes. If it still persists thrombus applies to any other method<sup>22</sup>.

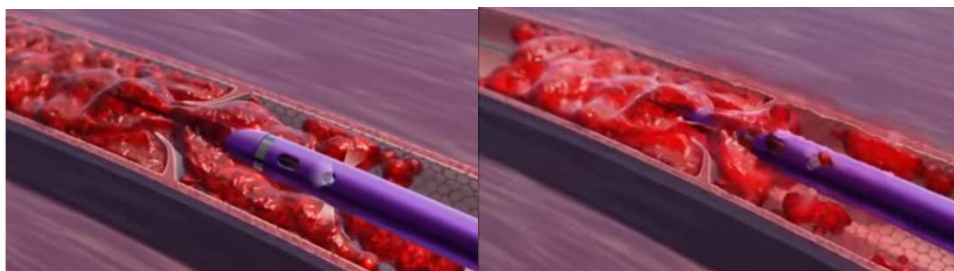
The protocol for the AngioJet<sup>®</sup> system: occlusion seen, cross clot with guide wire, system setup (8 step the old system, the new ultra 3 steps AngioJet<sup>®</sup>), set up system for power-pulse mode (unspike saline and exchange for thrombolytic), place AngioJet<sup>®</sup> at proximal end of thrombus formation, activation of the release of thrombolytic in the dose of about 10–20

mg tPA while AngioJet<sup>®</sup> moves forward/backward through the thrombus, waiting for about 30 min., excludes the thrombolytic, includes a saline solution, cross clot with AngioJet<sup>®</sup> while aspirating residual material, image vessel and assess progress, if there is residual thrombus entire procedure is repeated (maximum run time is 8–10 minutes depending on the model) (Figure 9). If it still persists thrombus applies to any other method. The advantage of ultrasound accelerated resolution of a thrombus over classical catheter for drug release is: reduced recanalization time, significantly lower risk of bleeding, shortness of in-hospital time. The advantage of ultrasound accelerated resolution of thrombus, over pharmacomechanical thrombolysis is using just one system, no hemolysis, minimal risk of distal embolization, no injuries of blood vessel wall and vein valves, complete resolution of the thrombus, significantly lower exposed dose to radiation of patients and staff.

Considering all the abovementioned EkoSonic<sup>®</sup> endovascular device imposes as the simplest, safest and most comfortable.



**Fig. 8 – Trellis system.**



**Fig. 9 – AngioJet system.**

We may ask why is so difficult to dissolve the thrombus? The fibrin network that is formed (the matrix) does not permit thrombolytic agents to penetrate inside of the thrombus, and thus is limited to access to plasminogen receptors sites. The reason is that they are embedded deep into thrombus during formation<sup>23</sup>. Speed of thrombolysis depends on ability to access the abovementioned receptor sites. EkoSonic<sup>TM</sup> Mach4 ultrasound energy leads to the dissolution of fibrin network, exposing sites for plasminogen receptors, leading to increased permeability of the thrombolytic and ultrasound waves reaching all the way to the vessel wall and the venous valves, not allowing thrombolytic to migrate into the circulation, thus the dissolution process is accelerated with a lower risk of unwanted bleeding<sup>12</sup> (Figure 10). A study by Francis et al.<sup>12</sup> shows that in relation to ultrasound accelerated thrombolysis, the dosage of given tPA is 48% greater after hour, 84% after 2 hours and 89% after 4 hours.

The difference in penetration of thrombolytic using an ordinary infusion catheter and EkoSonic<sup>TM</sup> system with the identical amounts of tPA for 15 minutes is as follows: 38% more penetrated with thrombus EkoSonic<sup>TM</sup> system compared to 17% with regular infusion catheter (Figure 11). Com-

ents resistant to conventional therapy in a shorter period of time vs drug delivery catheter.

### Conclusion

Our initial experience shows that all the patients achieved complete dissolution of the thrombus. There were no complications as bleeding, distal embolization, mechanical injury of the vessel wall, including the vein valves. The total dose of the given rTPA treatment in ultrasound accelerated thrombolysis ranged from 6 to 24 mg in the infusion that lasted from 6 to 24 hours. All the patients successfully achieved complete thrombus dissolution and established normal circulation immediately after the intervention. The prognostic outcome of patients limb salvage in spite of complete resolution of thrombus depends on the condition of distal microvascular circulation.

EkoSonic<sup>TM</sup> Mach4 is a minimally invasive method that carefully and completely dissolve thrombus in the arterial and venous system leading to reestablishment of the circulation (blood flow), with low risk of complications. The dose of tPA is 50–70% less than the implementation in protocols for systemic administration or other application of the above

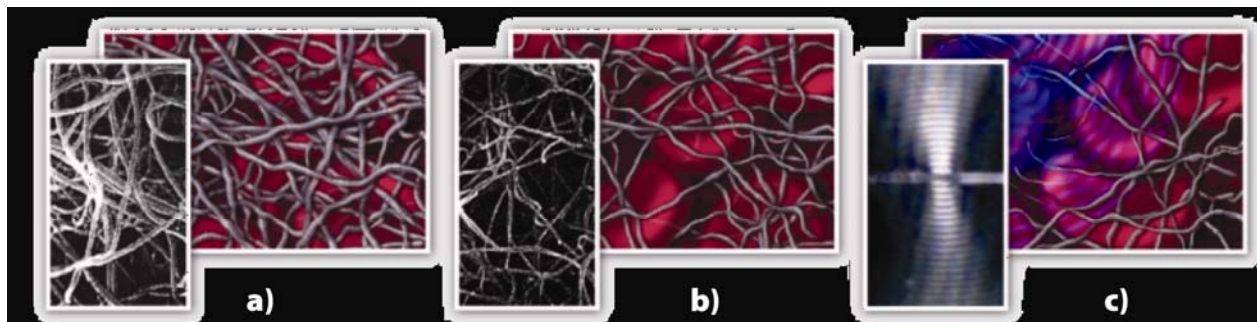


Fig. 10 – Fibrin network dissolution by: a) Only thrombolytic therapy; b) Only ultrasound; c) Ultrasound and thrombolytic therapy.

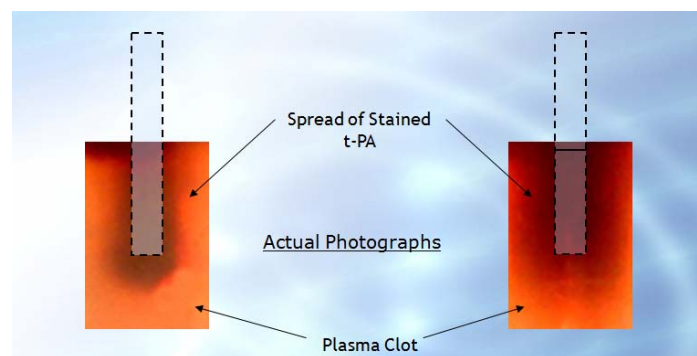


Fig. 11 – Dispersion of thrombolytic with a standard infusion catheter vs EkoSonic<sup>TM</sup> system.

parative overview of the thrombus dissolution with recombinant urokinase through a standard drug delivery catheter<sup>23</sup> and EkoSonic<sup>TM</sup> system<sup>10, 24</sup> with the percentage of bleeding demonstrated that more than 26% of patients treated with EkoSonic<sup>TM</sup> system had a complete dissolution of the thrombus, more than 82% reduction in bleeding and more than 75% of the dissolution of thrombus formation in pati-

methods, which gives minimal risk of bleeding, shortens the time of infusion and exposing time to radiation and length of in-hospital stay also. In patients who had recent surgery or trauma, thrombocytopenia, or other contraindications to systemic administration of thrombolytic therapy, or are refractory to conventional therapy, EkoSonic<sup>TM</sup> system has no alternative.

## R E F E R E N C E S

1. *Hajjar KA*. The endothelium in thrombosis and hemorrhage. In: *Loscalzo J, Shafer AI*, editors. *Thrombosis and Hemorrhage*. 3<sup>rd</sup> ed. Philadelphia: Lippincott Williams and Wilkins; 2003. p. 206–9.
2. *Verstaete M*. Haemostasis and thrombosis. In: *Julian DG, Camm JA, Hall RJ, Poolison PA*, et al, editors. *Diseases of the heart*. London: WB Saunders Company; 1996. p. 64–76.
3. *Davidge ST*. Prostaglandin H Synthase and Vascular Function. *Circ Res* 2001; 89(8): 650–60.
4. *Smyth EM, Fitzgerald GA*. Human prostacyclin receptor. *Vitam Horm* 2002; 65: 149–65.
5. *Marcus AJ, Broekman MJ, Drosopoulos JH, Islam N, Pinsky DJ, Sesti C*, et al. Metabolic control of excessive extracellular nucleotide accumulation by CD39/ecto-nucleotidase-1: implications for ischemic vascular diseases. *J Pharmacol Exp Ther* 2003; 305(1): 9–16.
6. *Ahmad SS, London FS, Walsh PN*. The assembly of the factor X-activating complex on activated human platelets. *J Thromb Haemost* 2003; 1(1): 48–59.
7. *Jurk K, Kebrel BE*. Platelets: physiology and biochemistry. *Semin Thromb Hemost* 2005; 31(4): 381–92.
8. *Ruggeri ZM*. Structure of von Willebrand factor and its function in platelet adhesion and thrombus formation. *Best Pract Res Clin Haematol* 2001; 14(2): 257–79.
9. *Ruggeri ZM*. Platelets in atherothrombosis. *Nat Med* 2002; 8(11): 1227–34.
10. *Grunwald MR, Hofmann LV*. Comparison of urokinase, alteplase, and reteplase for catheter-directed thrombolysis of deep venous thrombosis. *J Vasc Interv Radiol* 2004; 15(4): 347–52.
11. *Braaten JV, Goss RA, Francis CW*. Ultrasound reversibly disaggregates fibrin fibers. *Thromb Haemost* 1997; 78(3): 1063–8.
12. *Francis CW, Blinc A, Lee S, Cox C*. Ultrasound accelerates transport of recombinant tissue plasminogen activator into clots. *Ultrasound Med Biol* 1995; 21(3): 419–24.
13. *Soltani A, Singhal R, Garvia JL, Raju NR*. Absence of biological damage from prolonged exposure to intravascular ultrasound: A swine model. *Ultrasonics* 2007; 46(1): 60–7.
14. *Stambo GW, Gabriel Y*. Endovascular treatment of a chronically occluded limb of endograft with combination TNK pharmacological and EKOS thrombolytic catheter system. *Radiography* 2011; 17(1): 81–3.
15. *Rutherford RB, Baker JD, Ernst C, Johnston KW, Porter JM, Ahn S*, et al. Recommended standards for reports dealing with lower extremity ischemia: revised version. *J Vasc Surg* 1997; 26(3): 517–38.
16. *Novo S*. Classification, epidemiology, risk factors, and natural history of peripheral arterial disease. *Diabetes Obes Metab* 2002; 4(Suppl 2): S1–6.
17. *Mewis MW, Seabrook GR, Meissner MH, Cynamon J, Labropoulos N, Haughton SH*. Catheter-directed Thrombolysis for Lower Extremity Deep Venous Thrombosis: Report of a National Multicenter Registry. *Radiology* 1999; 211(1): 39–49.
18. *Hirsh J, Guzzati G, Albers GW, Harrington R, Schünemann HJ*. Antithrombotic and thrombolytic therapy, ACCP Guidelines. Antithrombotic and thrombolytic therapy. *Chest* 2008; 133(6 Suppl): 1105–25.
19. *Lang EV, Kulis AM, Villani M, Barnhart W, Balano R, Cohen R*. Hemolysis comparison between the OmniSonic OmniWave Endovascular System and the Possis AngioJet in a porcine model. *J Vasc Interv Radiol* 2008; 19(8): 1215–21.
20. *Dwarka D, Schwartz SA, Smyth SH, O'Brien MJ*. Bradyarrhythmias during use of the AngioJet system. *J Vasc Interv Radiol* 2006; 17: 1693–5.
21. *Salazar GM, Faintuch S, Gladstone S, Lang EV*. Abstract No. 373: In-Vitro Clot Removal and Particulate Analysis of the OmniWave™ Endovascular System and the Bacchus Trellis-8. *J Vasc Interv Radiol* 2008; 19(Suppl 2): S137.
22. *Soltani A, Volk KR, Hansmann DR*. Effect of constant versus variable ultrasound operating parameters on ultrasound-enhanced thrombolysis. *Cerebrovasc Dis* 2008; 26(Suppl 1): 1–20.
23. *Parikh S, Motarjeme A, McNamara T, Raabe R, Hagspiel K, Benenati JF*, et al. Ultrasound-accelerated thrombolysis for the treatment of deep vein thrombosis: initial clinical experience. *J Vasc Interv Radiol* 2008; 19(4): 521–8.
24. *Ouriel K, Veith FJ, Sasabara AA*. A Comparison of Recombinant Urokinase with Vascular Surgery as Initial Treatment for Acute Arterial Occlusion of the Legs. *New Engl J Med* 1998; 338(16): 1105–111.
25. EKOS in vitro data on file. Available from: [www.ekoscorp.com/.../Mach4e%20PR%20final%20](http://www.ekoscorp.com/.../Mach4e%20PR%20final%20)

Received on March 28, 2015.

Revised on May 18, 2015.

Accepted on May 19, 2015.

Online First March, 2016.